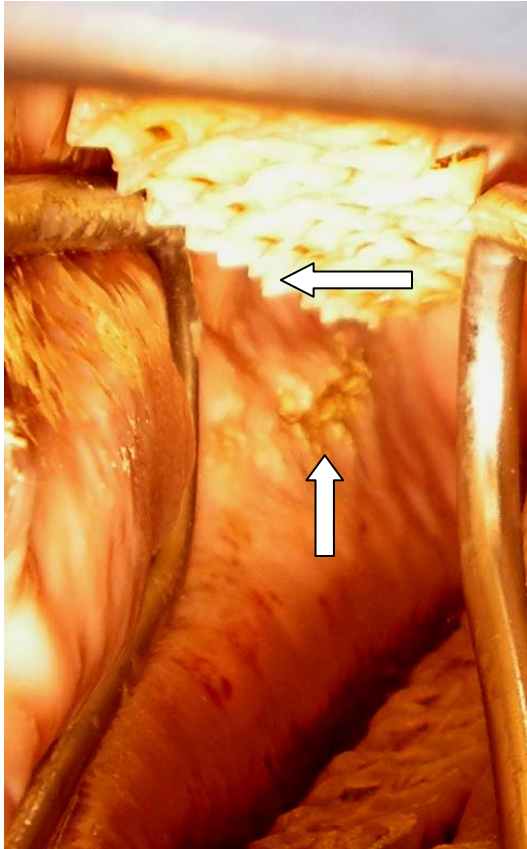


This photograph of the inside of a horse's mouth displays oral ulceration. These were caused by the sharp dental "points" on the outside of his upper cheek teeth. Horses' teeth emerge from their sockets continually throughout their life. As they grind food, they sharpen the outer edge of their upper teeth and the inner edge of their lower teeth. Routine dental care, typically performed once yearly, can make horses more comfortable, allow them to accept pressure from the bit and bridle more willingly, and enable them to chew and digest food more efficiently.



Vertical arrow—oral ulcerations  
Horizontal arrow—dental points